

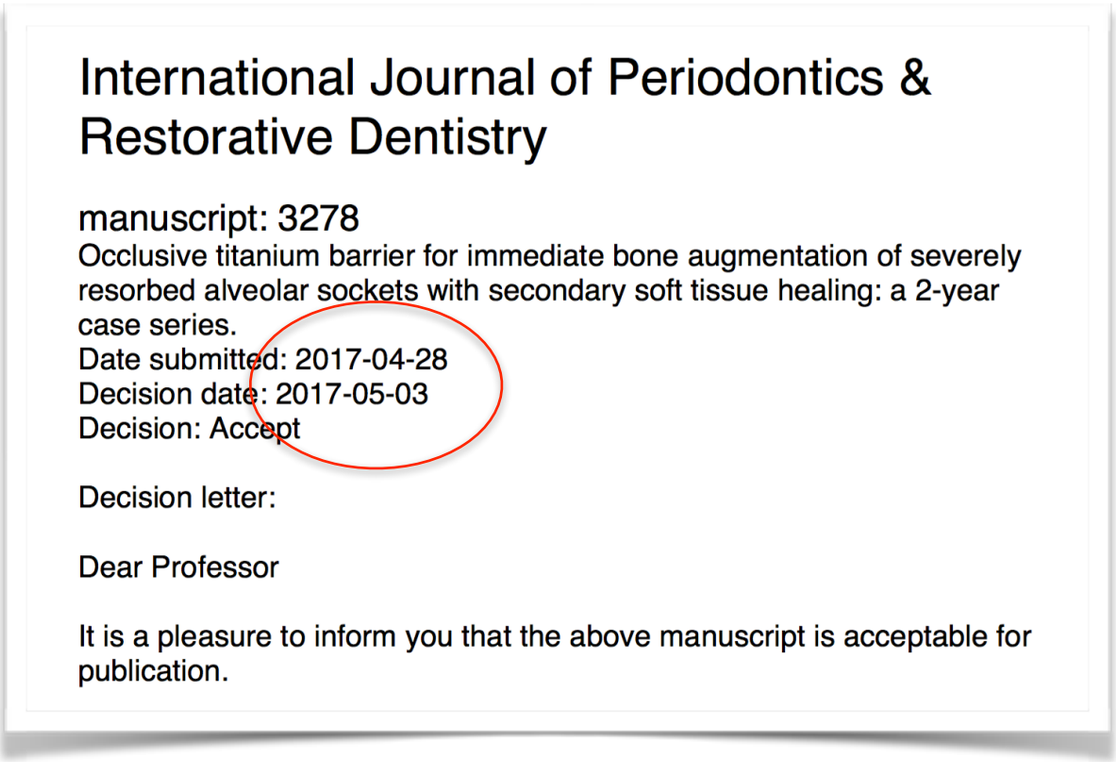

International Journal of Periodontics & Restorative Dentistry

manuscript: 3278
Occlusive titanium barrier for immediate bone augmentation of severely resorbed alveolar sockets with secondary soft tissue healing: a 2-year case series.
Date submitted: 2017-04-28
Decision date: 2017-05-03
Decision: Accept

Decision letter:

Dear Professor

It is a pleasure to inform you that the above manuscript is acceptable for publication.

"Occlusive titanium barrier for immediate bone augmentation of severely resorbed alveolar sockets with secondary soft tissue healing: a 2-year case series."

Fabio Perret, Federica Romano, Francesco Ferrarotti, Mario Aimetti

Accepted for publication in MAY 2017

REGENPLATE®

CASE 1

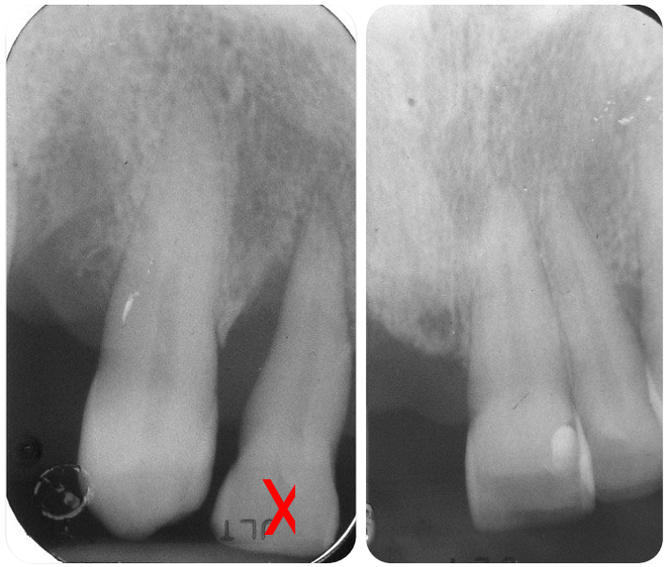

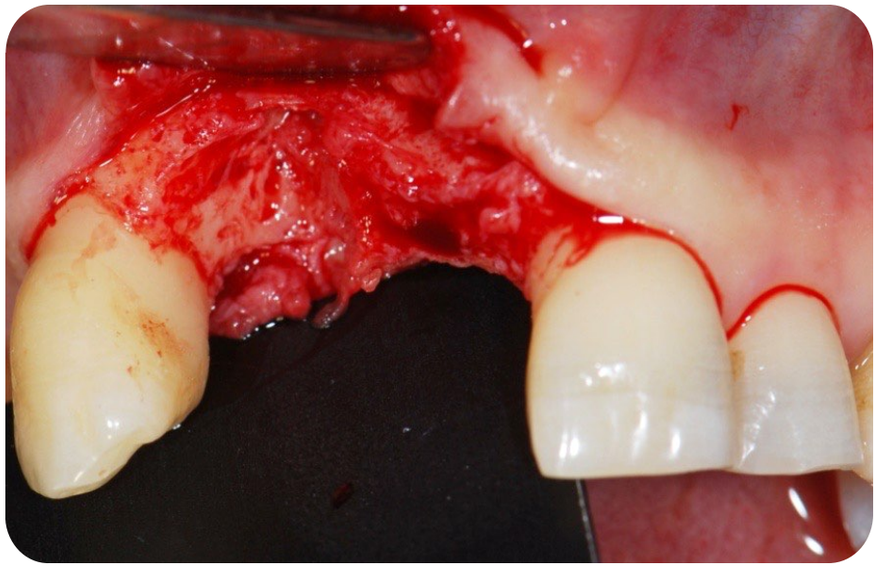

fig.1 and 2- the bone defect immediately after extraction

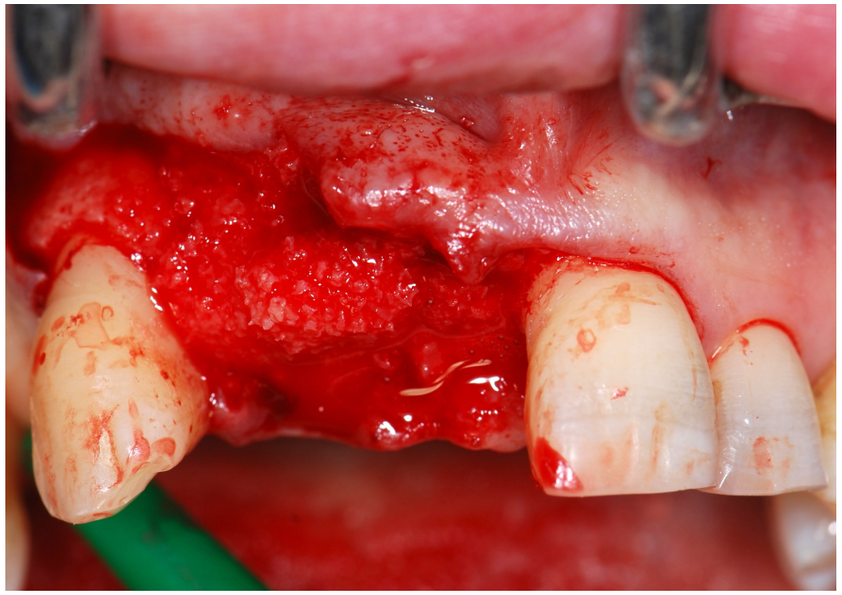

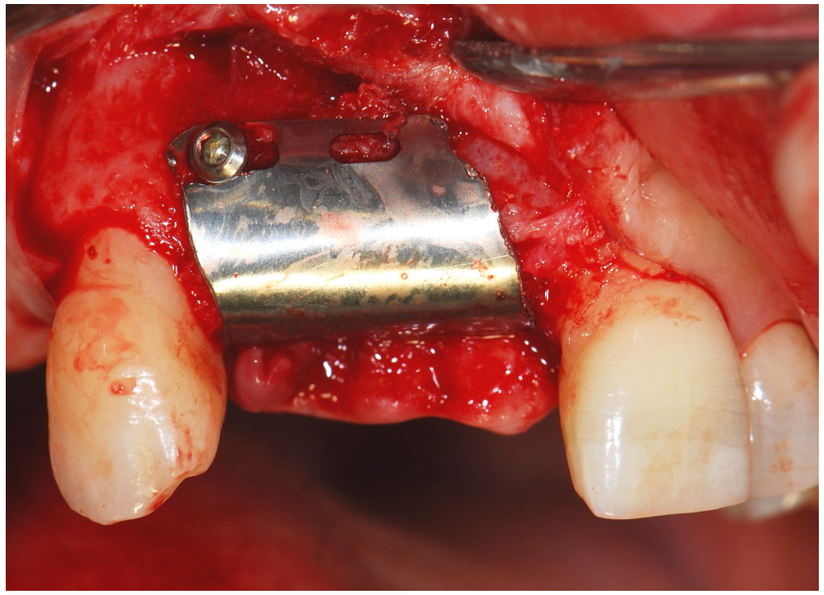

fig. 3 and 4- The socket was filled with particulate mineralized cancellous bovine bone chips, and the titanium barrier secured by two mini-screws or micro-pins on the buccal and/or lingual side of the ridge crest

REGENPLATE®

CASE 1

BASELINE

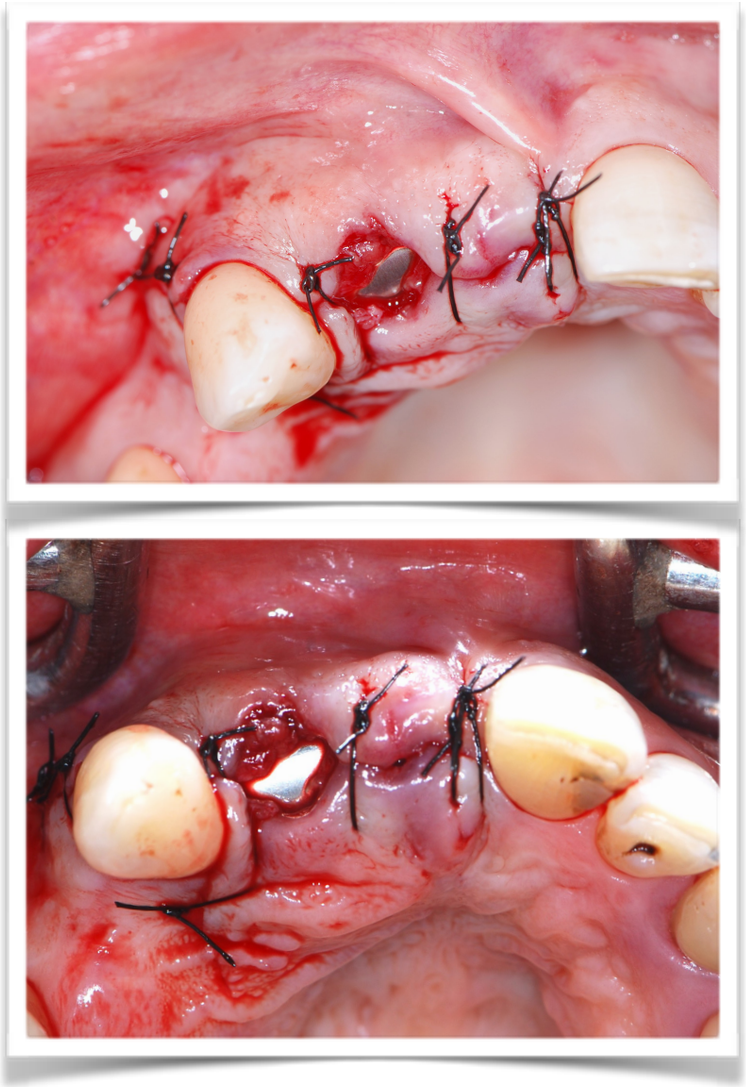

1 MONTH

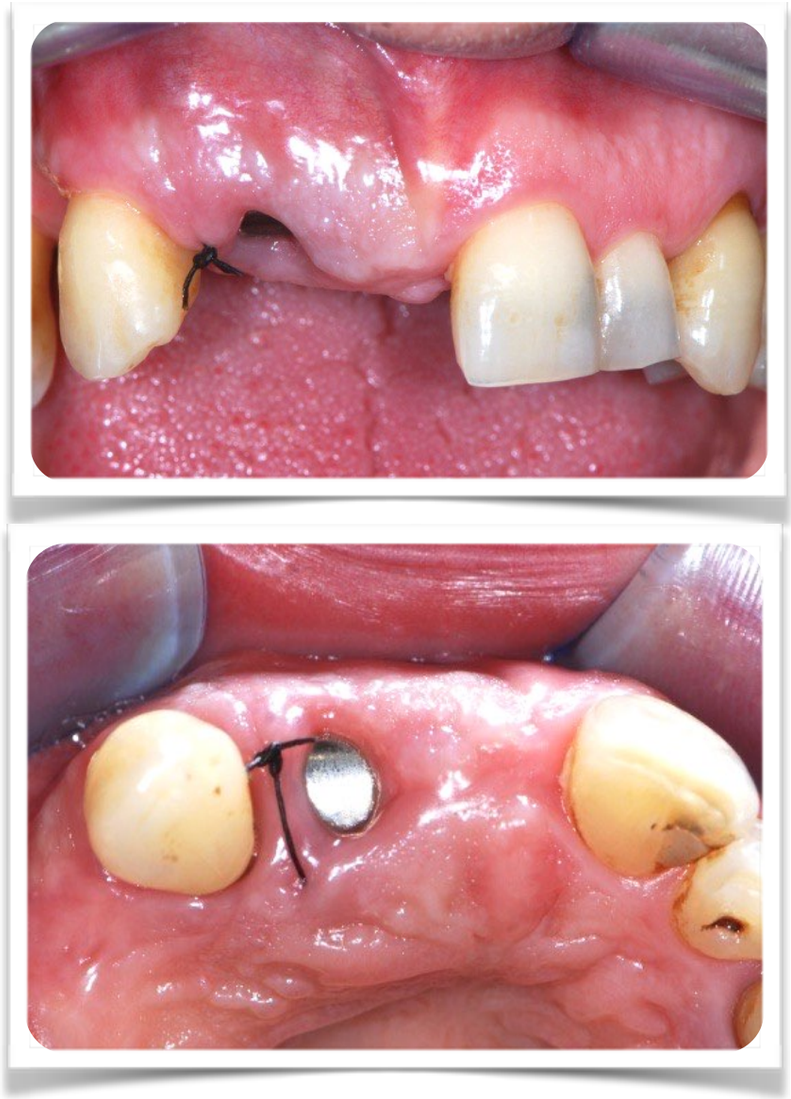

4 MONTHS

fig. 5 –10: The flaps were repositioned and secured with horizontal internal mattress sutures and interrupted sutures. The membrane remained partially exposed in the oral environment and a secondary soft tissue healing was intentionally left.

"The external surface is developed to be resistant to the bacterial biofilm adhesion, even in case of accidental exposure"

REGENPLATE®

CASE 1

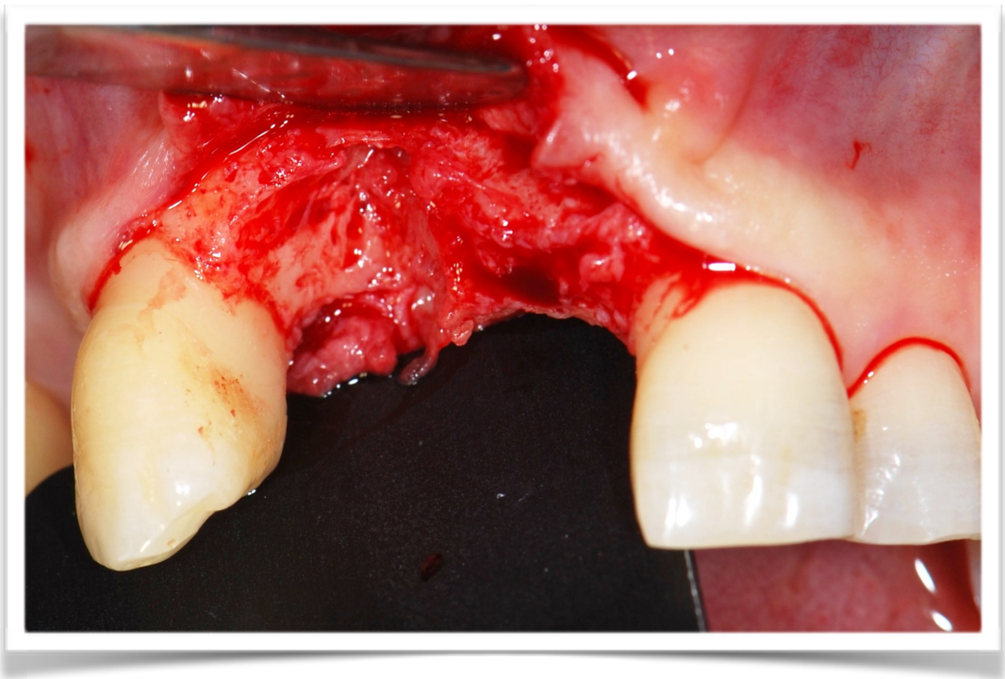

6 months

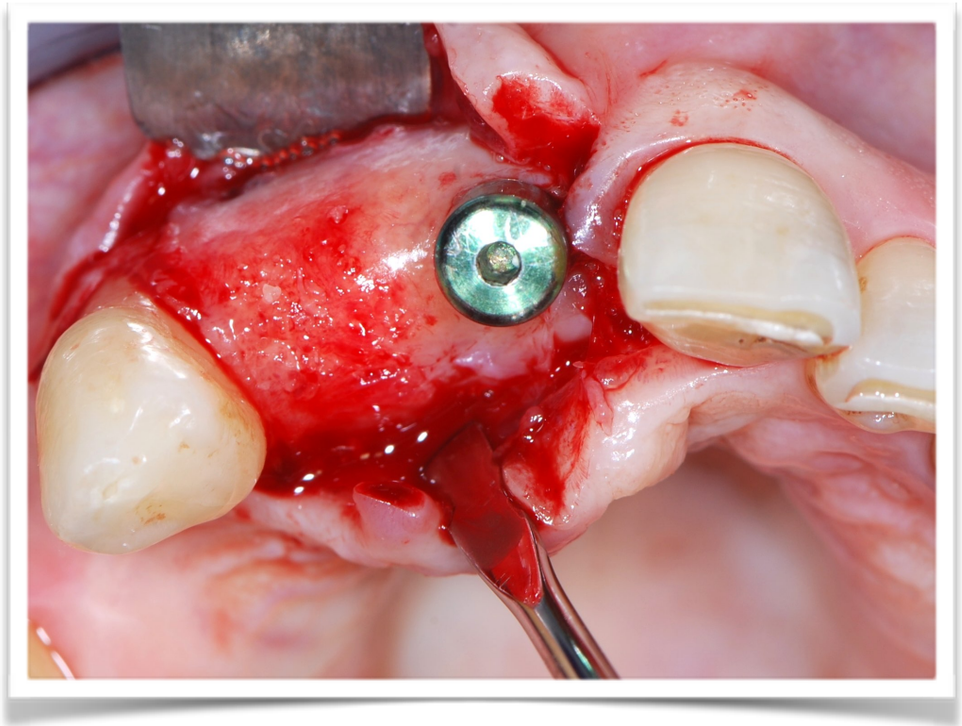

the newly formed hard tissue

REGENPLATE®

CASE 1

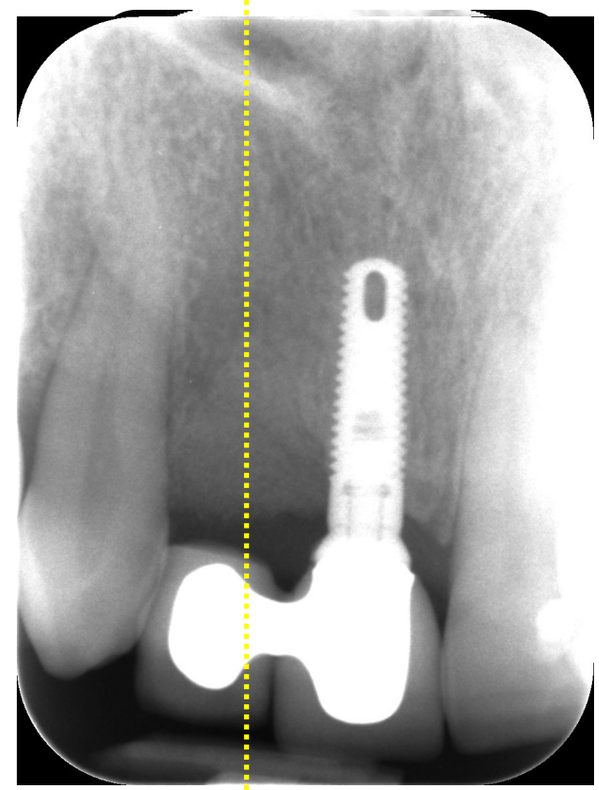

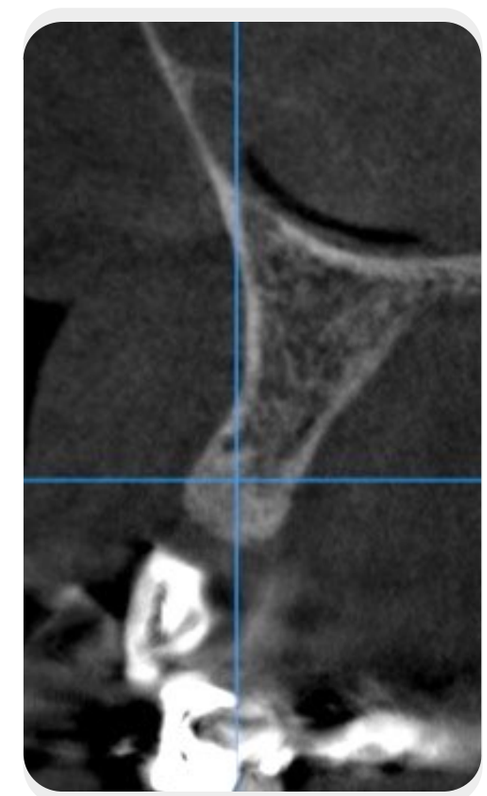

baseline

36 months follow-up

REGENPLATE®

CASE 2

fig.1 and 2- the baseline

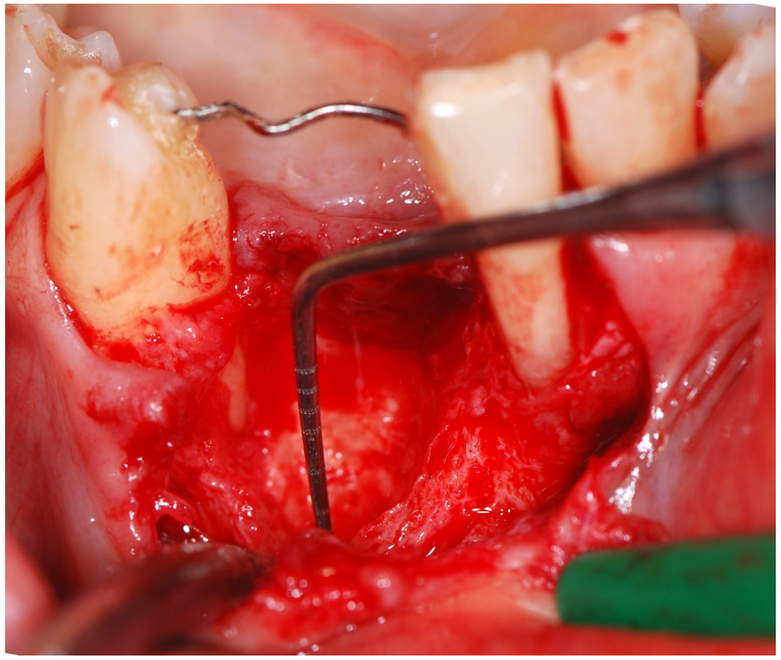

fig.3- the bone defect after extraction

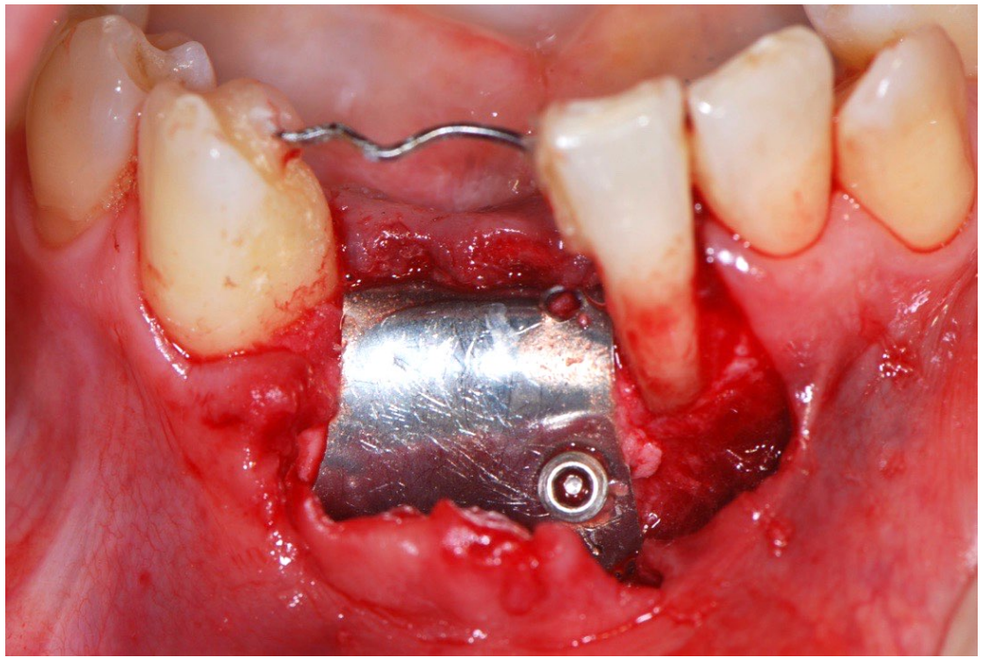

fig.4- the graft and the titanium membrane fixed with pins

REGENPLATE®

CASE 2

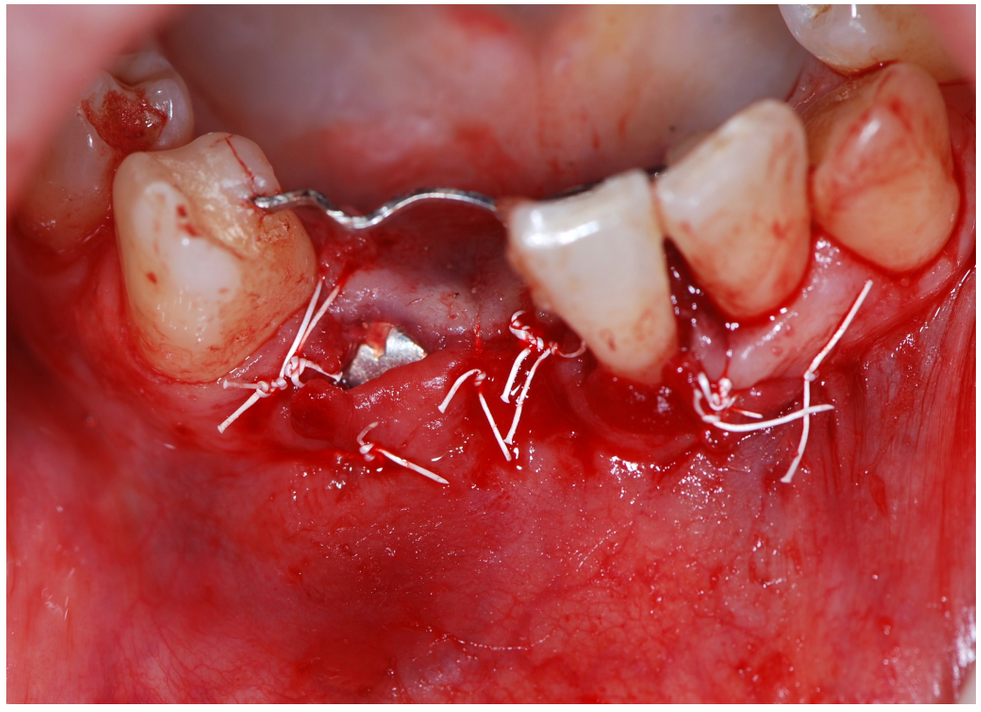

fig.5- the suture and the membrane partially exposed

fig.6- the soft tissue healing at 4 months

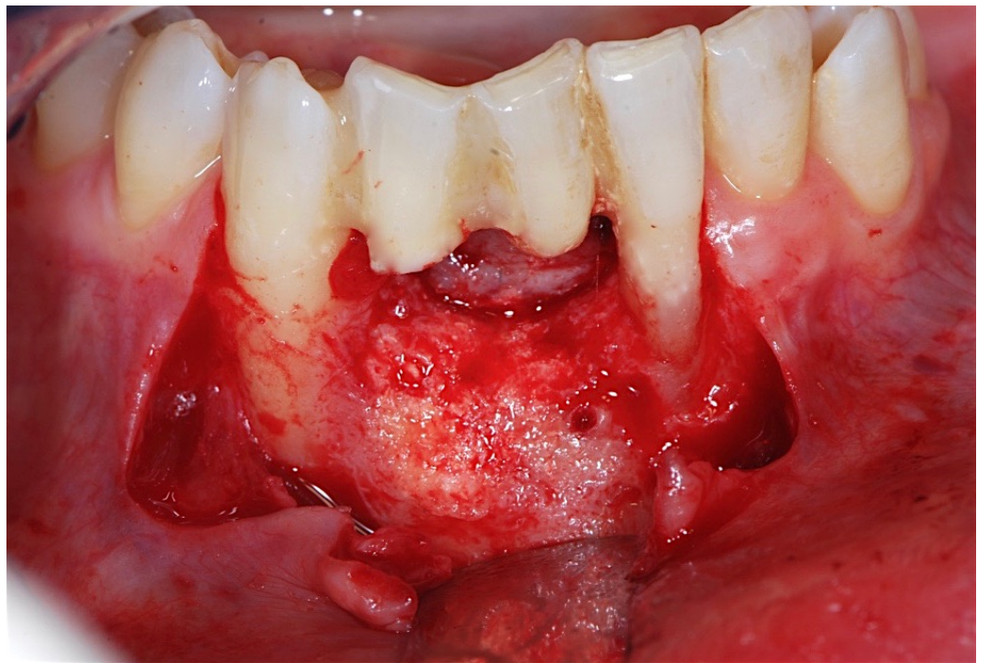

fig.7- the newly formed hard tissue

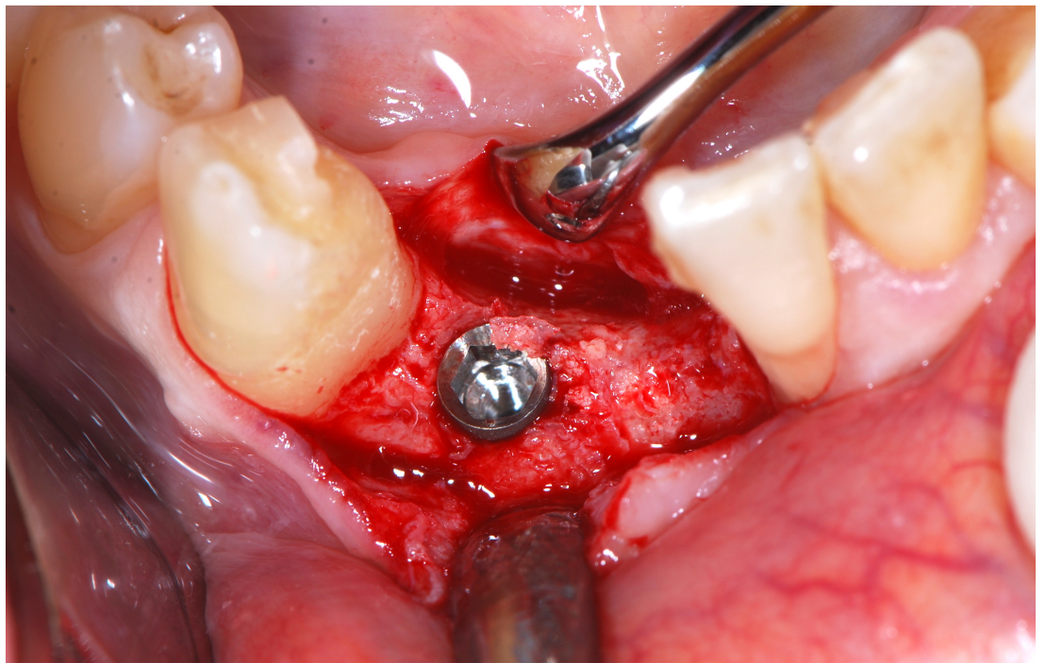

fig.8- the implant insertion (torque: 45 Ncm)

REGENPLATE®

CASE 2

fig.9- the tissue conditioning

fig.10- the final ceramic crowns

fig.11- the blue arrow shows the presence of the bone peak, even if low

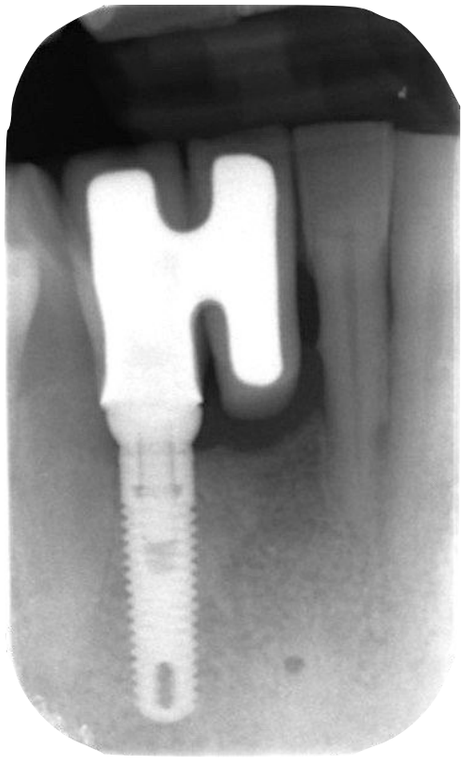

fig.12- 12 months of loading with the temporary crowns

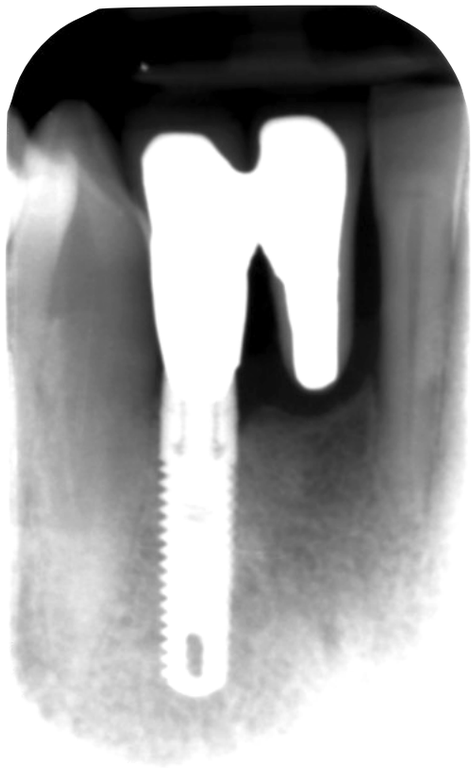

fig.12- 24 months of loading with the final ceramic crowns

CASE 3: vertical GBR

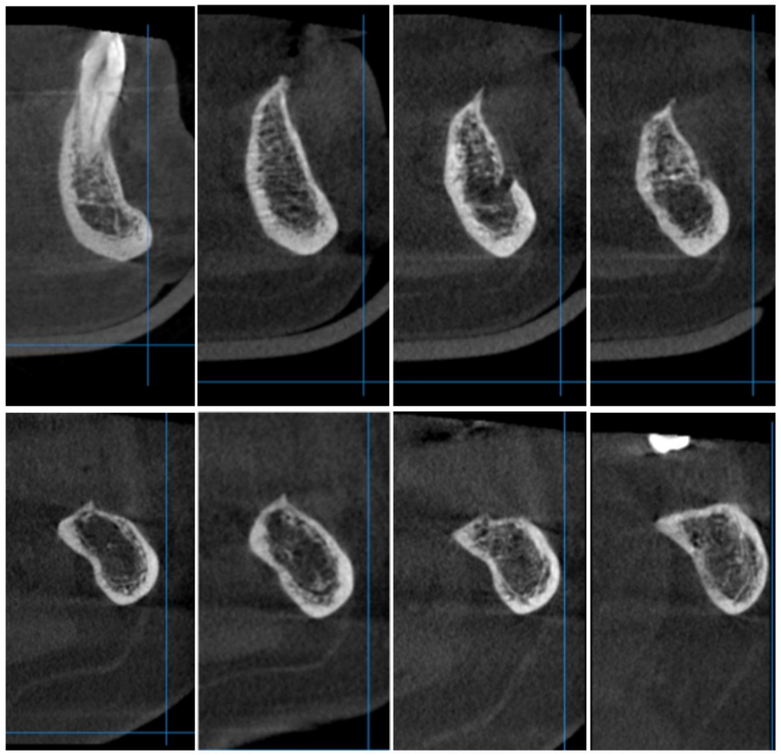

baseline

REGENPLATE®

CASE 3

step1: shaping of membrane

step 2: particulate mineralized cancellous bovine bone

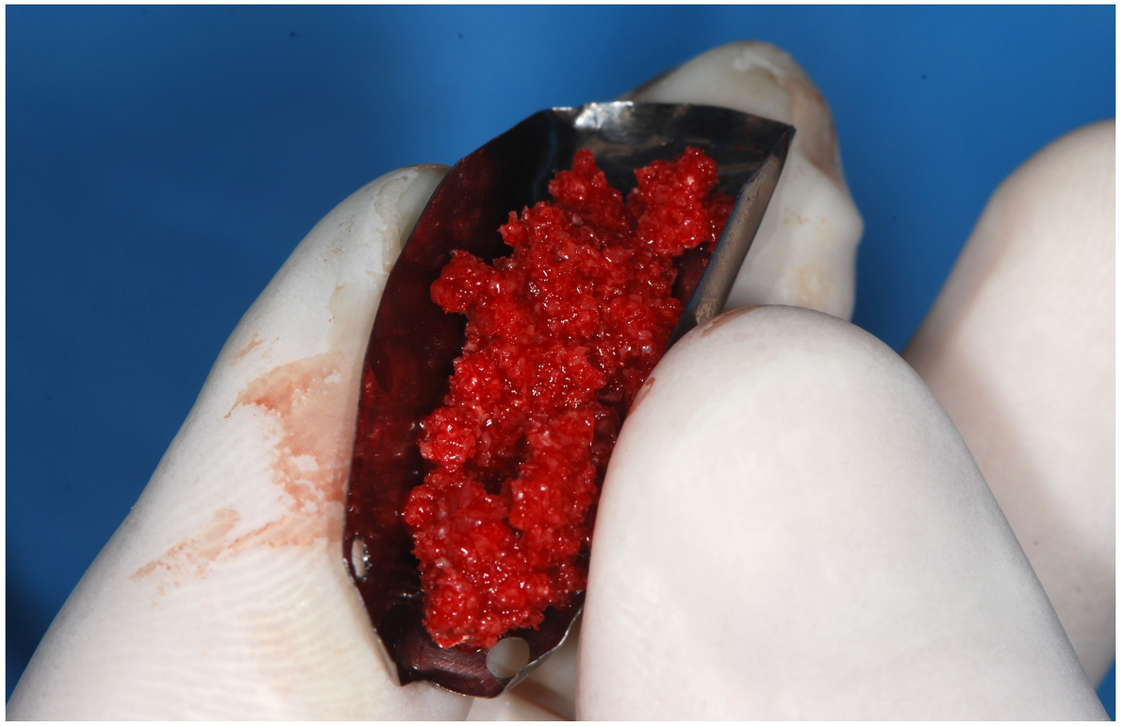

step 3: the graft inside the membrane

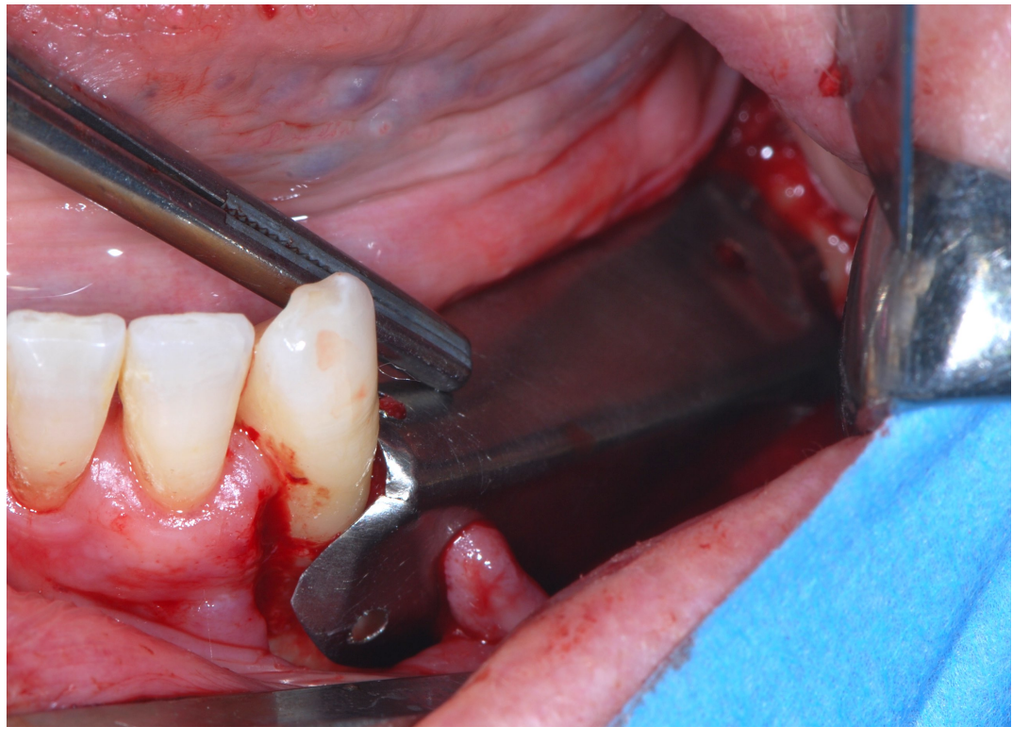

step 4: membrane fixation
(it does not requires lingual fixation)

REGENPLATE®

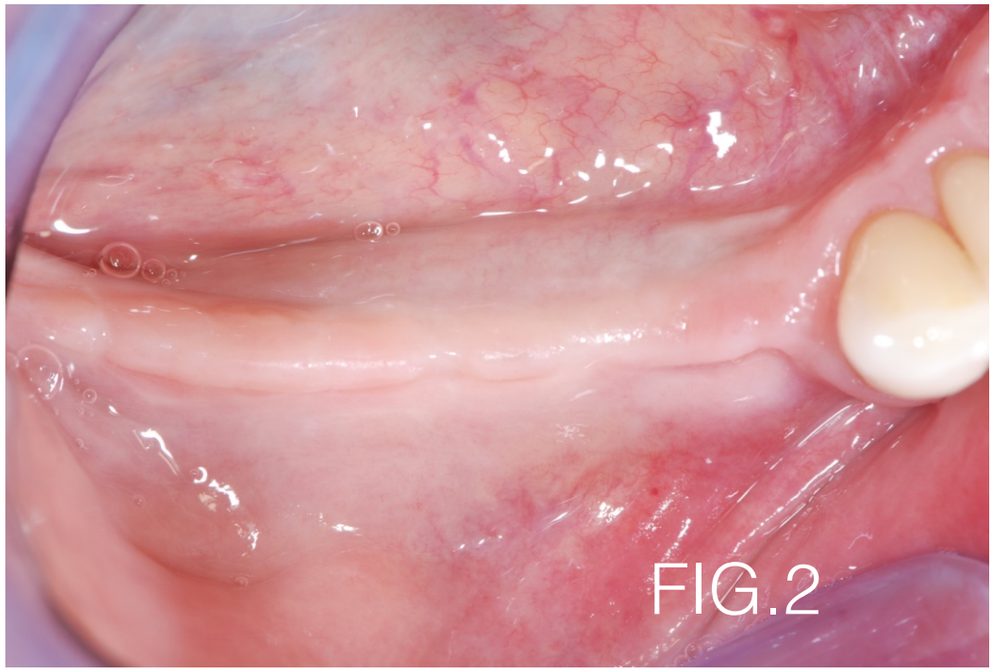

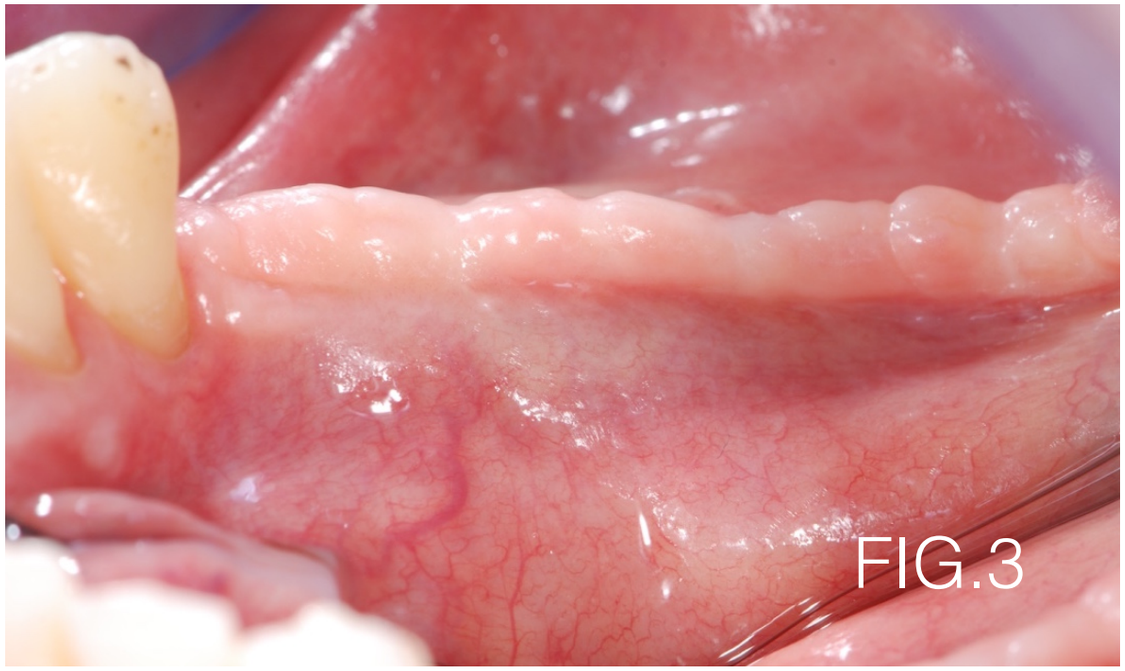

Fig. 1-2-3 : the good soft tissue thickness and health

REGENPLATE®

CASE 3

before

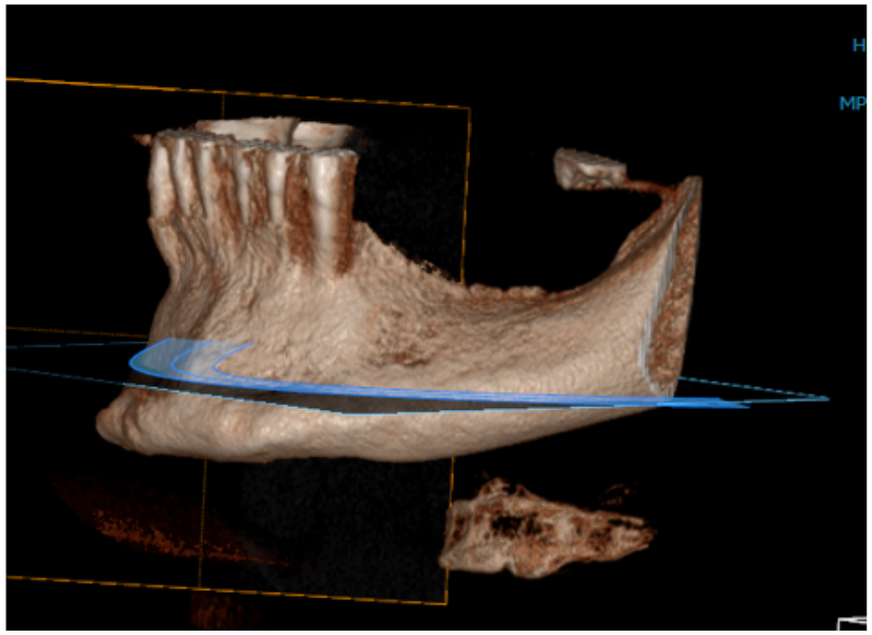

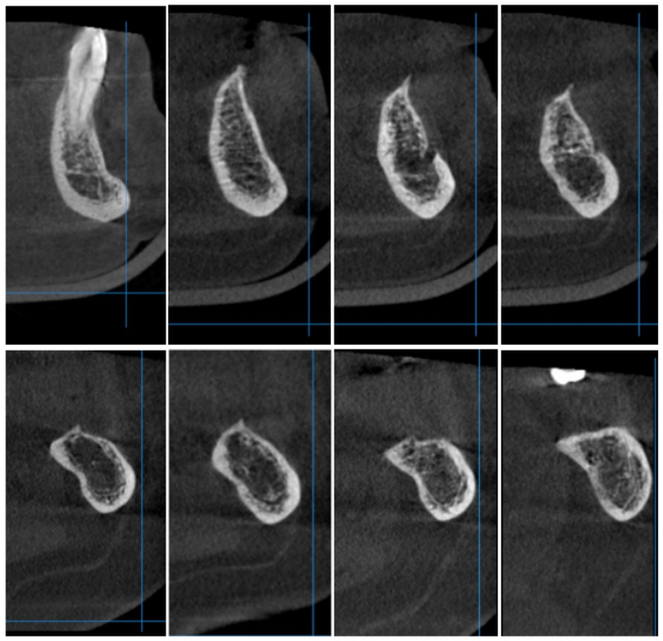

after
(8 months)

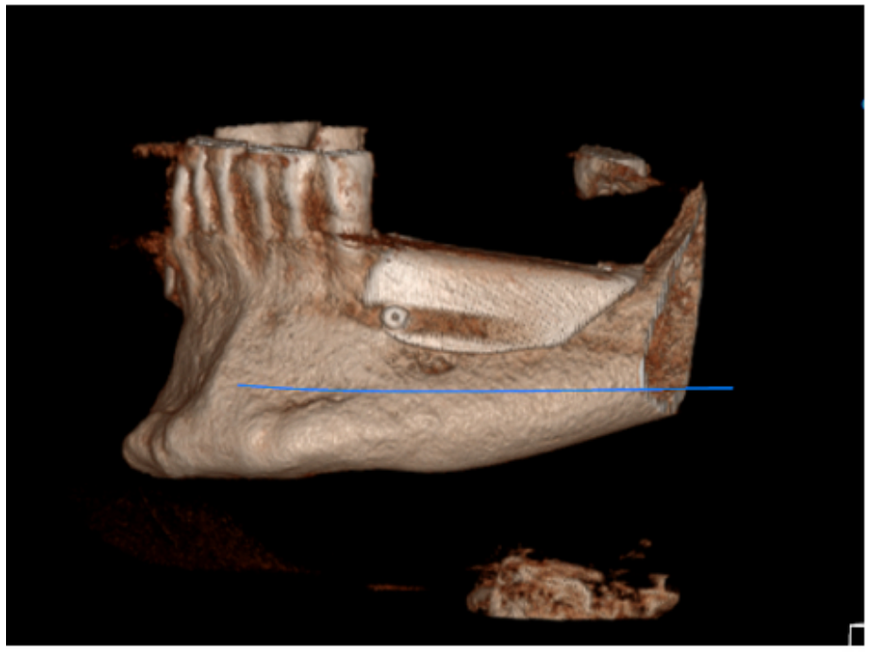

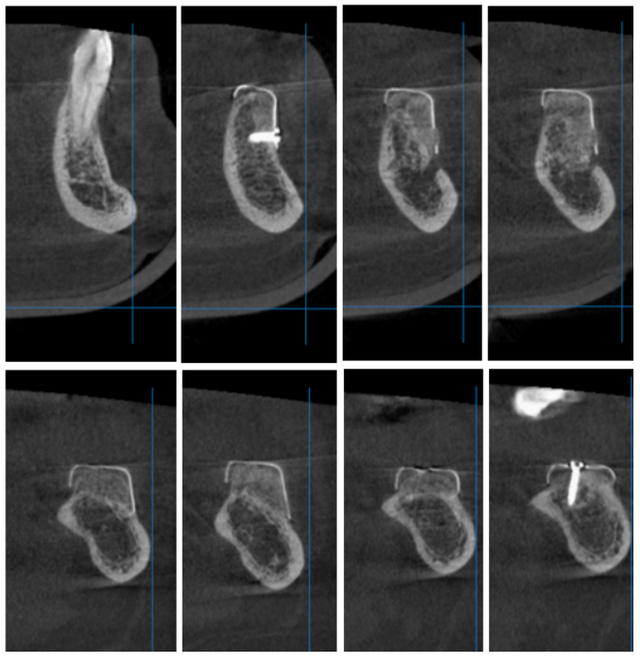

Schmid J, Hammerle CH, Olah AJ, Lang NP. Membrane **permeability is <u>unnecessary</u>** for guided generation of new bone. An experimental study in the rabbit. Clin Oral Implants Res 1994;5:125-130.

CASE 3

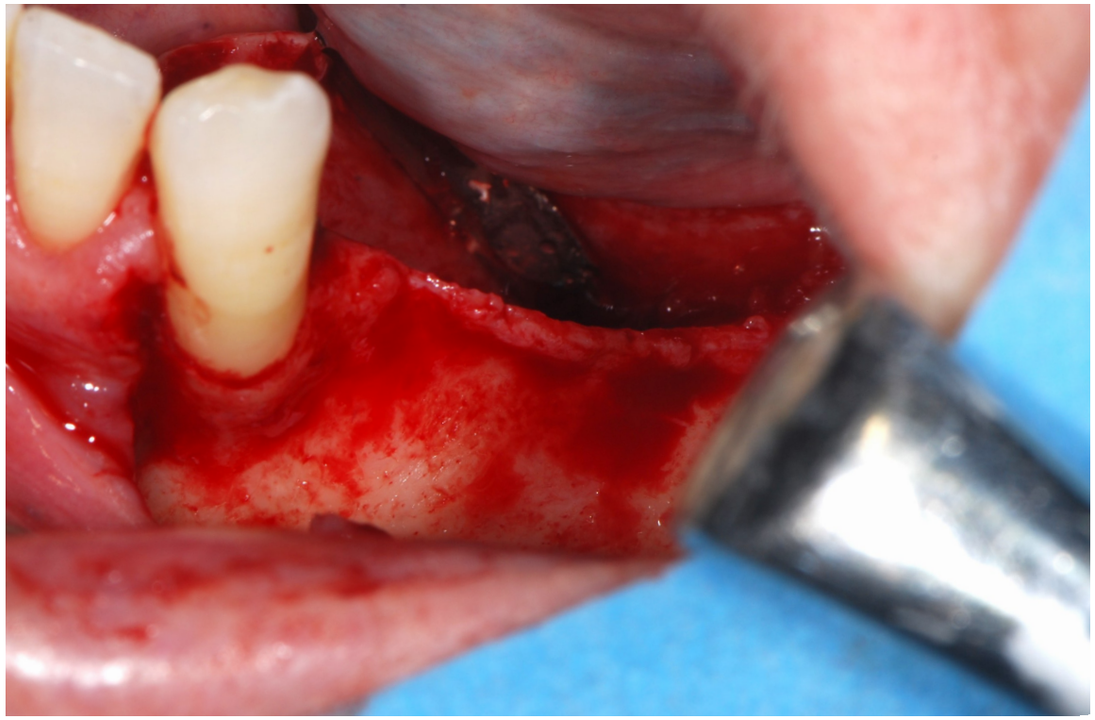

BASELINE

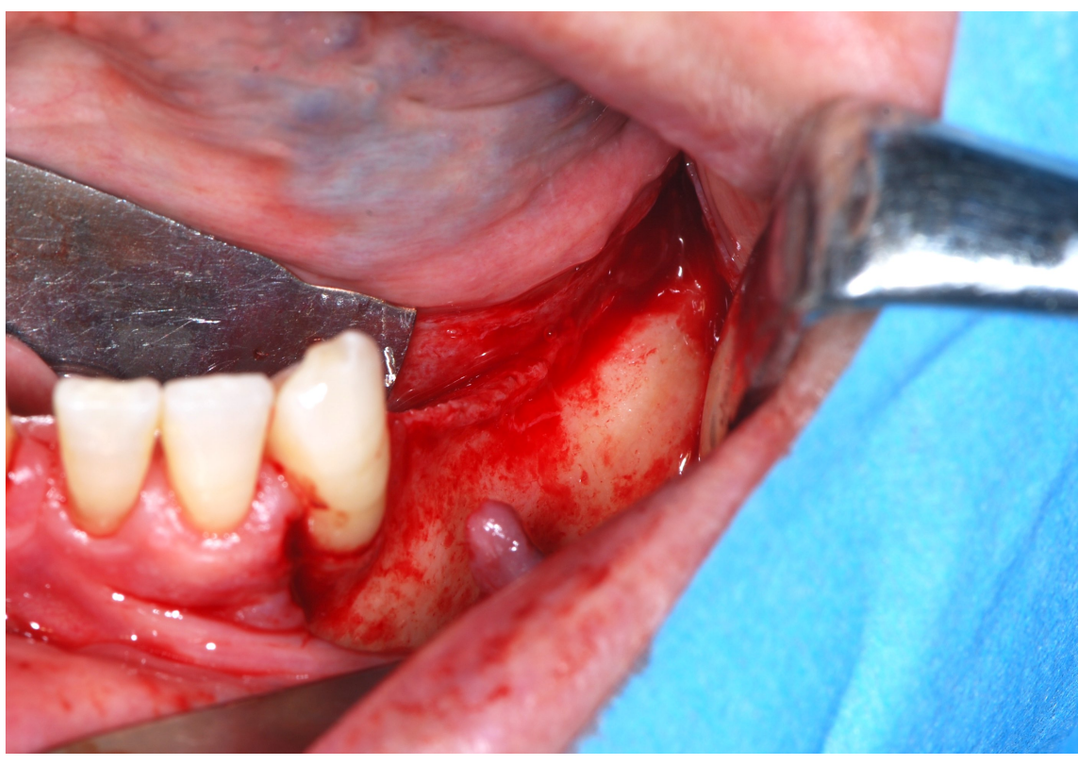

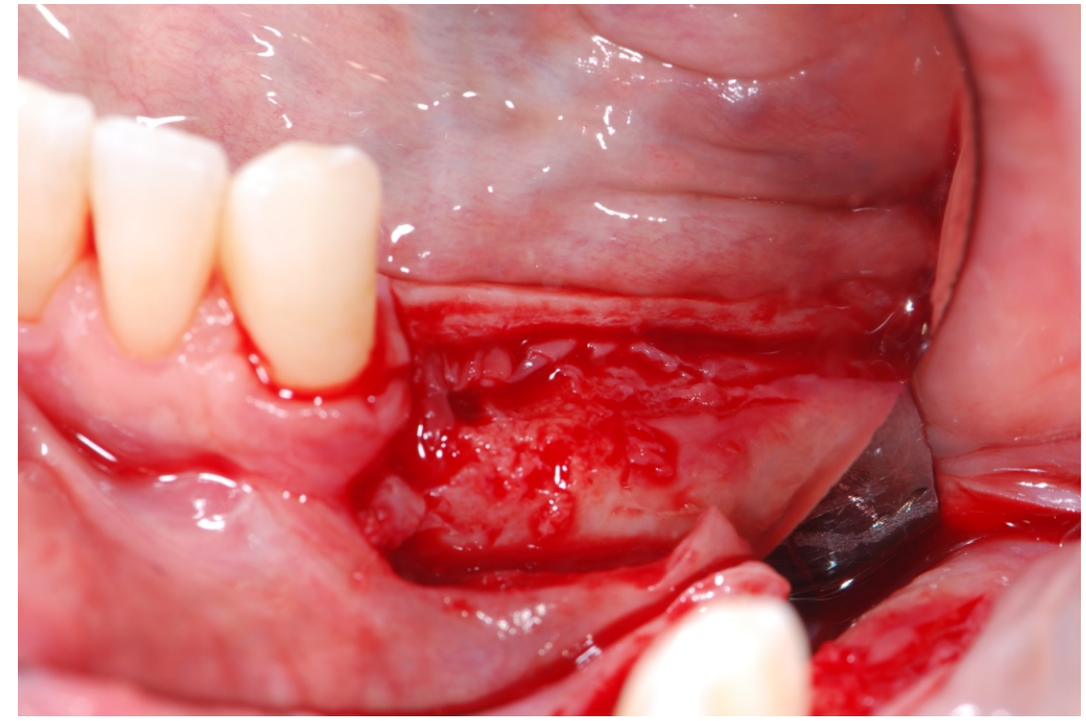

8 MONTHS

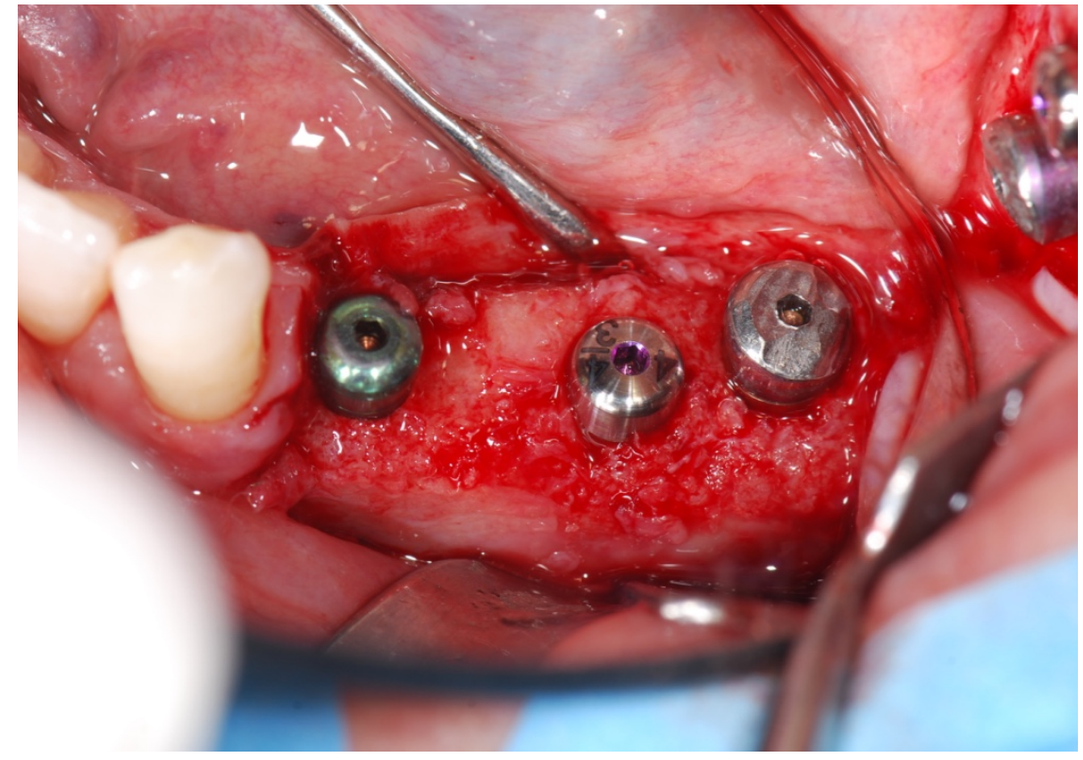

watch the video of the 2°stage surgery here: https://youtu.be/yeAcHtE2AZs

CASE 3

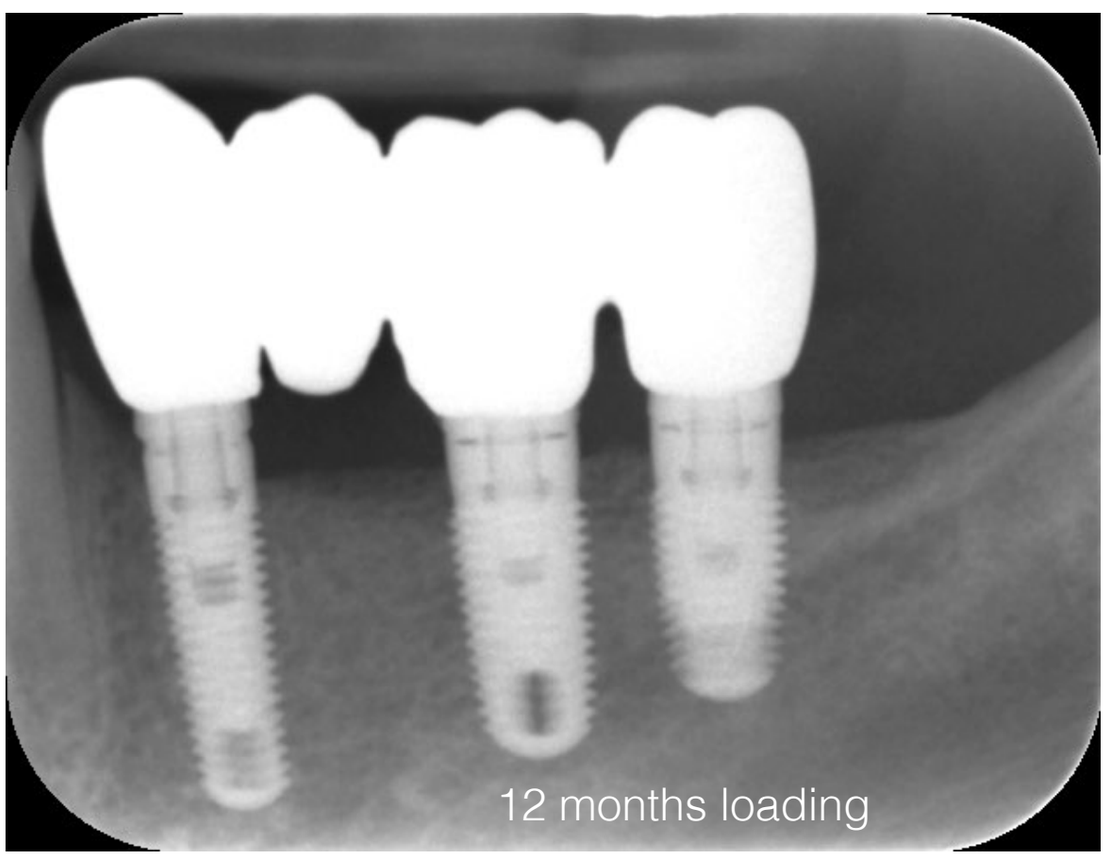

REGENPLATE®

CASE 3

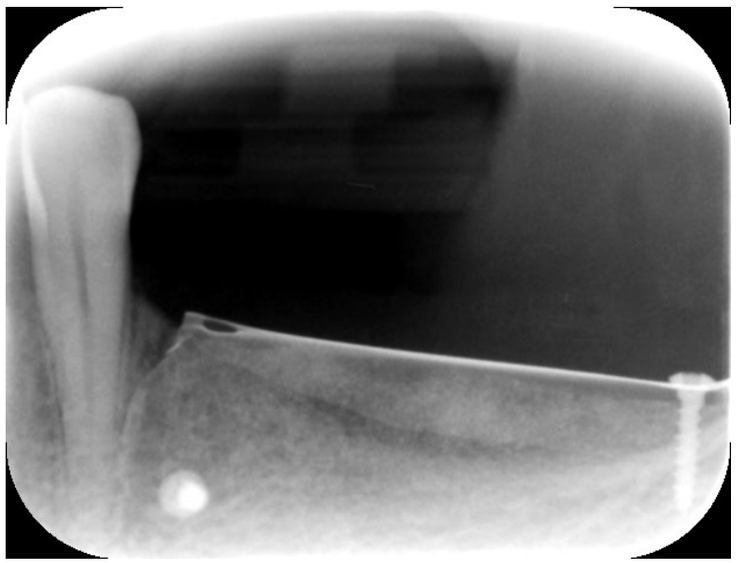

baseline

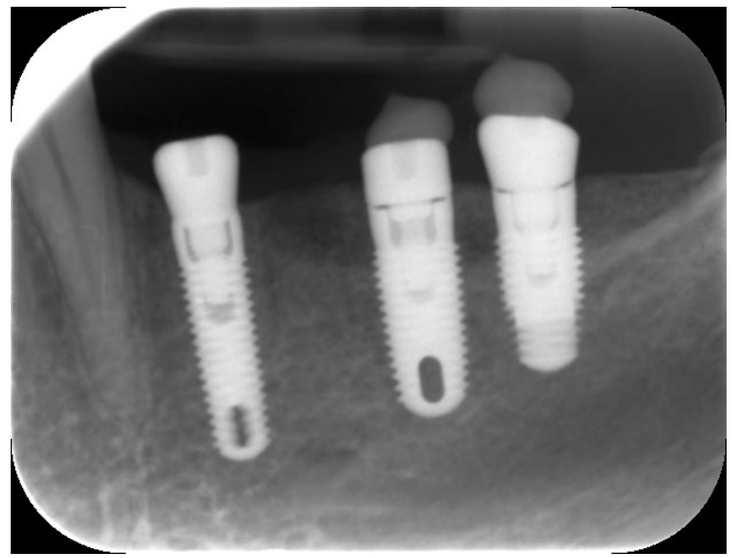

8 months: implant placement

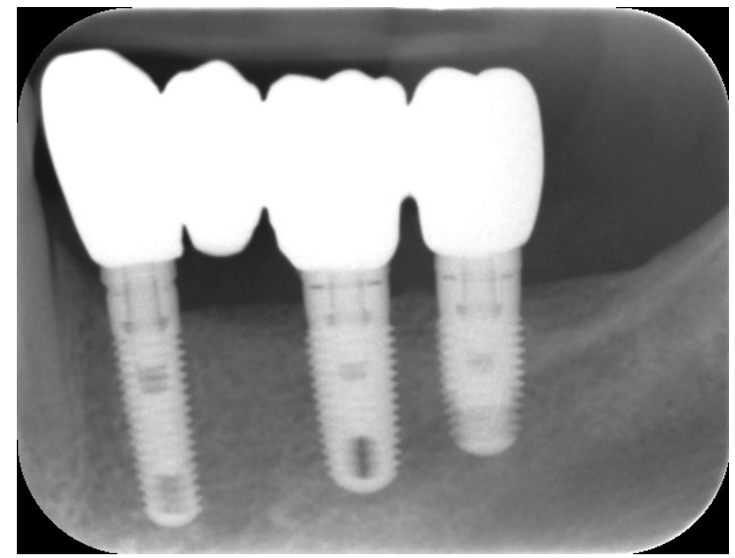

12 months loading

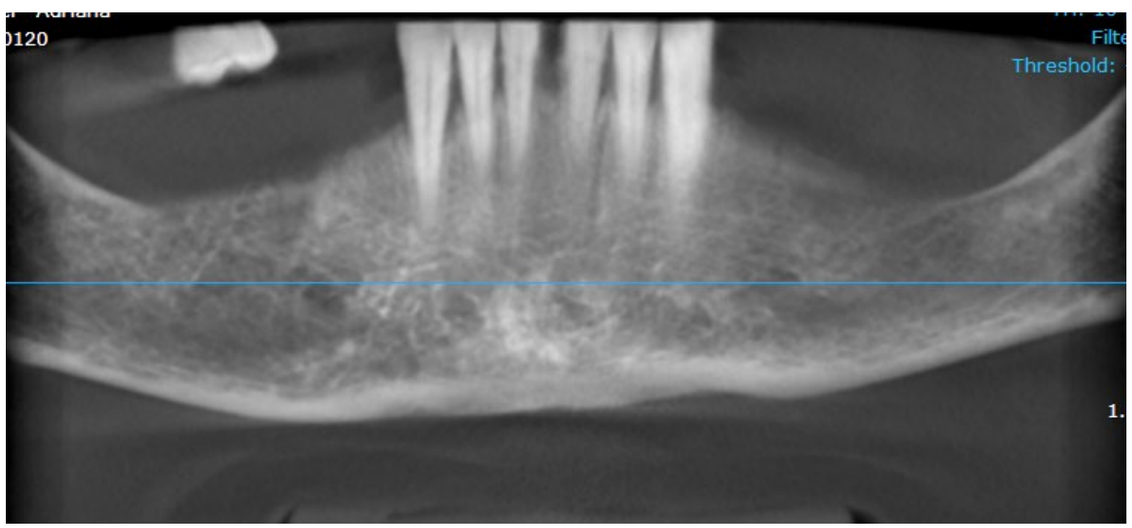

baseline

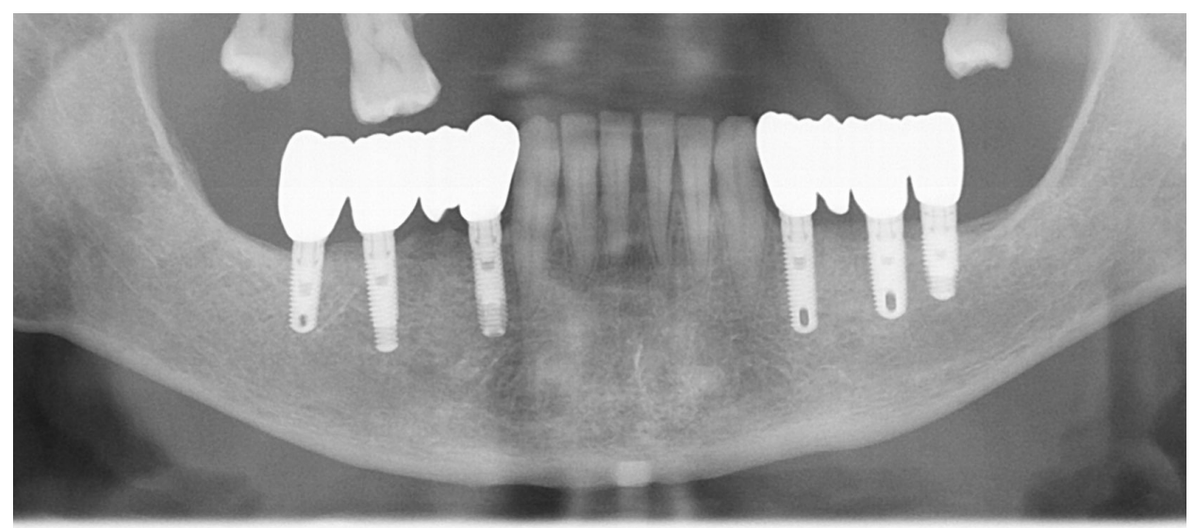

6 months loading

REGENPLATE®

BIBLIOGRAPHY

1. Lundgren, D, Lundgren AK, Sennerby L, Nyman, S. Augmentation of intramembraneous bone beyond the skeletal envelope using an occlusive titanium barrier. An experimental study in the rabbit. Clin Oral Implants Res 1995;6:67-72.

2. Yamada Y, Nanba K, Ito K. Effects of occlusiveness of a titanium cap on bone generation beyond the skeletal envelope in the rabbit calvarium. Clin Oral Implants Res. 2003 Aug;14(4):455-63.

3. Van Steenberghe D, Johansson C, Quirynen M, Molly L, Albrektsson T, Naert I. Bone augmentation by means of a stiff occlusive titanium barrier. Clin Oral Implants Res 2003;14:63-71.

4. Molly L, Quirynen M, Michiels K, Van Steenberghe D. Comparison between jaw bone augmentation by means of a stiff occlusive titanium membrane or an autologous hip graft: a retrospective clinical assessment. Clin Oral Implants Res 2006;17:481-487.

5. Schmid J, Hammerle CH, Olah AJ, Lang NP. Membrane permeability is unnecessary for guided generation of new bone. An experimental study in the rabbit. Clin Oral Implants Res 1994;5:125-130.